


Grand Rounds



Maya Bitar, M.D.

University of Louisville

Department of Ophthalmology and Visual Sciences

10/08/10

Presentation

CC: “Left eye turns out”

HPI: 1 year-old AAM was brought to Pediatric Ophthalmology clinic by mom who noticed intermittent outward deviation of the left eye for a few months. The deviation was occurring first around 10% of waking hours but it has progressed and is now occurring almost 50% of waking hours.

POH: None

PMH: None. Full term birth, normal birth weight.

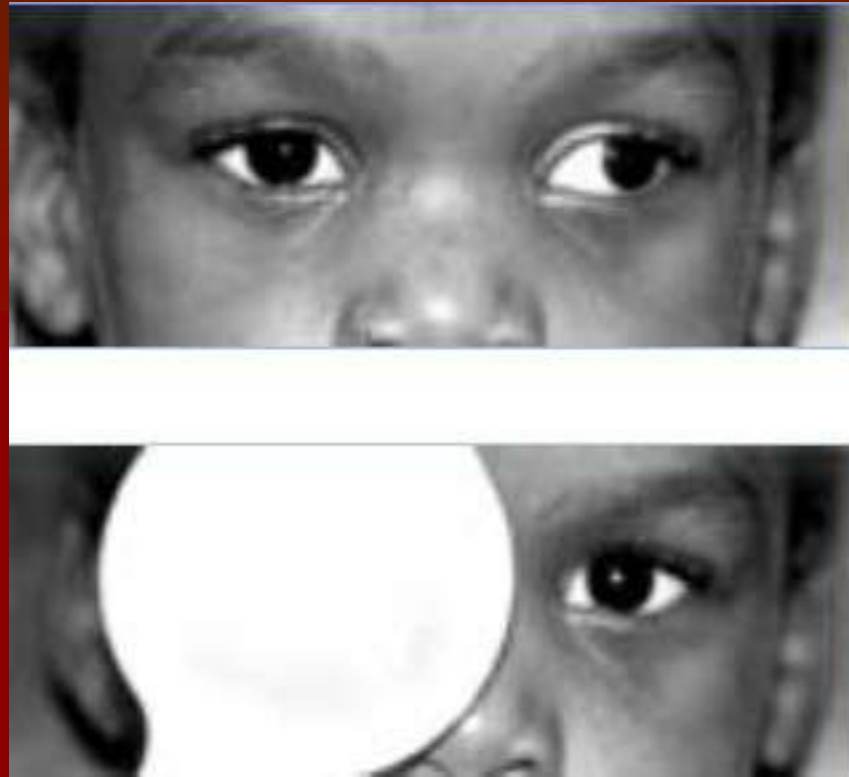MEDS: None

Allergy: Amoxicillin

ROS: No recent illness or trauma. Otherwise healthy


Objective

	OD	OS
<u>VA(sc):</u> (Binocular fixation test)	Central Steady Maintained	Central Steady Unmaintained (2-3 sec)
<u>Pupils:</u>	4 → 2 brisk OU, no RAPD	4 → 2

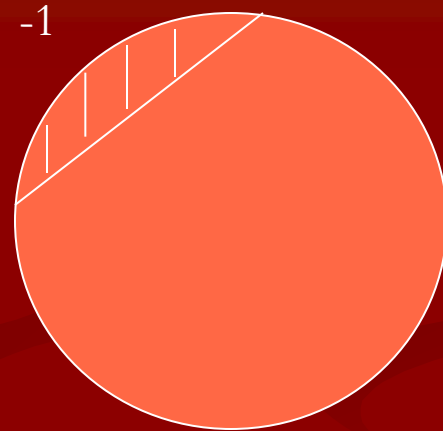


Cover Test: Left intermittent exotropia LX(T)

Motility:



35 diopter LX(T)
at distance and
near (alternate
cover prism test)



Office Control of X(T):

blinks to control the deviation

Cycloplegic Retinoscopy: (2% Cyclopentolate, 2.5%
Phenylephrine)

OD -0.50 +1.50 x110

OS -0.50 +1.50 x85

PLE: WNL OU

DFE: WNL OU

Assessment

1 year-old AAM with:

1. Basic left intermittent exotropia with fair control
2. Amblyopia OS
3. Mixed astigmatism OU

- What is the best course of management at this point?

Management

- Treatment of amblyopia with patch to OD 4h/d
- Reassess in 2-3 weeks
- Consider corrective lenses

Intermittent Exotropia

- The most common form of exotropia
- Prevalence of 1% in children younger than 11 years
- More common in the Middle East, Subequatorial Africa and Asia
- More common in girls
- Risk factors:
 - Maternal smoking/chemical substance abuse during pregnancy
 - Low birth weight
 - Positive family history

Clinical features

- Onset is in most cases shortly after birth
- Spontaneous drifting out of one eye observed when the patient is tired, sick or daydreaming or after consuming alcohol or sedatives
- Diplophotophobia
- Transient diplopia/blurry vision
- Asthenopia with prolonged reading
- Micropsia

Physical examination

1) Assessing office control of X(T):

➤ Subjective method

- Good: “breaks” only after cover testing and resumes fusion without need for a blink or refixation

- Fair: blinks or refixates to control the deviation after disruption with cover testing

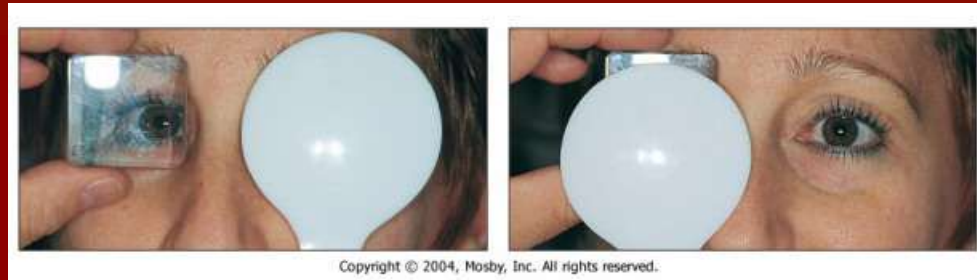
- Poor: spontaneously breaks or who does not regain alignment despite blink or refixation

➤ Objective method

- Distance stereoacuity

Near stereoacuity: marker for deterioration

2) Measuring the angle of deviation:
Alternate prism cover testing at distance and at near



Classification

	Distance deviation	Near Deviation
Basic		$\pm 10 \Delta$
Divergence excess		$> 10 \Delta$
Convergence insufficiency		$< 10 \Delta$

- ❖ Pseudo-divergence excess: from tenacious proximal fusion. Near deviation increases within 10Δ of the distance deviation after 30 min of patching.

Natural History

- Most X(T) are progressive ¹
- Signs of progression:
 - Gradual loss of fusional control- increasing frequency of manifest squint
 - Development of secondary convergence insufficiency
 - Increase in size of the basic deviation
 - Development of suppression-absence of diplopia during manifest phase
 - Decrease of stereoacuity

Management

- Medical Treatment:
 - Temporizing measure
 - Preferred in:
 - patients with small deviations ($<20\Delta$) with excellent control
 - very young patients - risk of amblyopia from surgical overcorrection
 - patients with medical contraindication to surgery

Medical management

- Correction of refractive error, particularly useful in myopes
- Overcorrecting minus lens therapy³
- Part time occlusion: reevaluate after 4 months
- Prism therapy
- Orthoptics

Surgical Management

■ Indications:

- preservation or restoration of binocular fusion
- cosmesis

■ Timing:

- controversial before 4 y of age
- most have intermittent fusion and excellent stereopsis

Surgical treatment

- delayed surgery:

- . avoids consecutive esotropia and amblyopia
- . allows more accurate measurements

- early surgery:

- . prevents development of sensory changes

=> reserved for patients with rapid loss of control

Type of Surgery

- Bilateral Lateral Rectus Recession:
 - preferred in true divergence excess
- Recession of Lateral Rectus with Medial Rectus Resection:
 - preferred in amblyopia
- Bilateral Medial Rectus Resection:
 - preferred in convergence insufficiency

References

1. Von Noorden GK. *Some aspects of exotropia. Presented at Wilmers Residents' Association, John Hopkins Hospital, Baltimore April 26. 1966.*
2. Jeff A. McKenzie, BA; Jason A. Capo, MD; Kevin J. Nusz, MD; Nancy N. Diehl, BS; Brian G. Mohny, MD *Prevalence and Sex Differences of Psychiatric Disorders in Young Adults Who Had Intermittent Exotropia as Children. Arch Ophthalmol. 2009;127(6):743-747*
3. Watts P, Tippings E, Al-Madfai H. *Intermittent exotropia, overcorrecting minus lenses, and the Newcastle scoring system. J AAPOS. 2005 Oct;9(5):460-4.*
4. Abroms AD, Mohny BG, Rush DP, Parks MM, Tong PY. *Timely surgery in intermittent and constant exotropia for superior sensory outcome. Am J Ophthalmol. 2001 Jan;131(1):111-6.*

Thank You!